ChatGPT’s diagnostic performance based on textual vs. visual information compared to radiologists’ diagnostic performance in musculoskeletal radiology

Horiuchi *et al. European Radiology* (2025) 35:506–516
https://doi.org/10.1007/s00330-024-10902-5

EUROPEAN SOCIETY OF RADIOLOGY
European Radiology

IMAGING INFORMATICS AND ARTIFICIAL INTELLIGENCE Open Access

Check for updates

ChatGPT's diagnostic performance based on textual vs. visual information compared to radiologists' diagnostic performance in musculoskeletal radiology

Daisuke Horiuchi[1], Hiroyuki Tatekawa[1], Tatsushi Oura[1], Taro Shimono[1], Shannon L. Walston[1], Hirotaka Takita[1], Shu Matsushita[1], Yasuhito Mitsuyama[1], Yukio Miki[1] and Daiju Ueda[1,2*]

Abstract

Objectives To compare the diagnostic accuracy of Generative Pre-trained Transformer (GPT)-4-based ChatGPT, GPT-4 with vision (GPT-4V) based ChatGPT, and radiologists in musculoskeletal radiology.

Materials and methods We included 106 "Test Yourself" cases from *Skeletal Radiology* between January 2014 and September 2023. We input the medical history and imaging findings into GPT-4-based ChatGPT and the medical history and images into GPT-4V-based ChatGPT, then both generated a diagnosis for each case. Two radiologists (a radiology resident and a board-certified radiologist) independently provided diagnoses for all cases. The diagnostic accuracy rates were determined based on the published ground truth. Chi-square tests were performed to compare the diagnostic accuracy of GPT-4-based ChatGPT, GPT-4V-based ChatGPT, and radiologists.

Results GPT-4-based ChatGPT significantly outperformed GPT-4V-based ChatGPT ($p < 0.001$) with accuracy rates of 43% (46/106) and 8% (9/106), respectively. The radiology resident and the board-certified radiologist achieved accuracy rates of 41% (43/106) and 53% (56/106). The diagnostic accuracy of GPT-4-based ChatGPT was comparable to that of the radiology resident, but was lower than that of the board-certified radiologist although the differences were not significant ($p = 0.78$ and 0.22, respectively). The diagnostic accuracy of GPT-4V-based ChatGPT was significantly lower than those of both radiologists ($p < 0.001$ and < 0.001, respectively).

Conclusion GPT-4-based ChatGPT demonstrated significantly higher diagnostic accuracy than GPT-4V-based ChatGPT. While GPT-4-based ChatGPT's diagnostic performance was comparable to radiology residents, it did not reach the performance level of board-certified radiologists in musculoskeletal radiology.

Clinical relevance statement GPT-4-based ChatGPT outperformed GPT-4V-based ChatGPT and was comparable to radiology residents, but it did not reach the level of board-certified radiologists in musculoskeletal radiology. Radiologists should comprehend ChatGPT's current performance as a diagnostic tool for optimal utilization.

*Correspondence:
Daiju Ueda
ai.labo.ocu@gmail.com
[1]Department of Diagnostic and Interventional Radiology, Graduate School of Medicine, Osaka Metropolitan University, Osaka, Japan
[2]Department of Artificial Intelligence, Graduate School of Medicine, Osaka Metropolitan University, Osaka, Japan

Key Points

- *This study compared the diagnostic performance of GPT-4-based ChatGPT, GPT-4V-based ChatGPT, and radiologists in musculoskeletal radiology.*
- *GPT-4-based ChatGPT was comparable to radiology residents, but did not reach the level of board-certified radiologists.*
- *When utilizing ChatGPT, it is crucial to input appropriate descriptions of imaging findings rather than the images.*

Keywords Artificial intelligence, Natural language processing, Radiology

Graphical Abstract

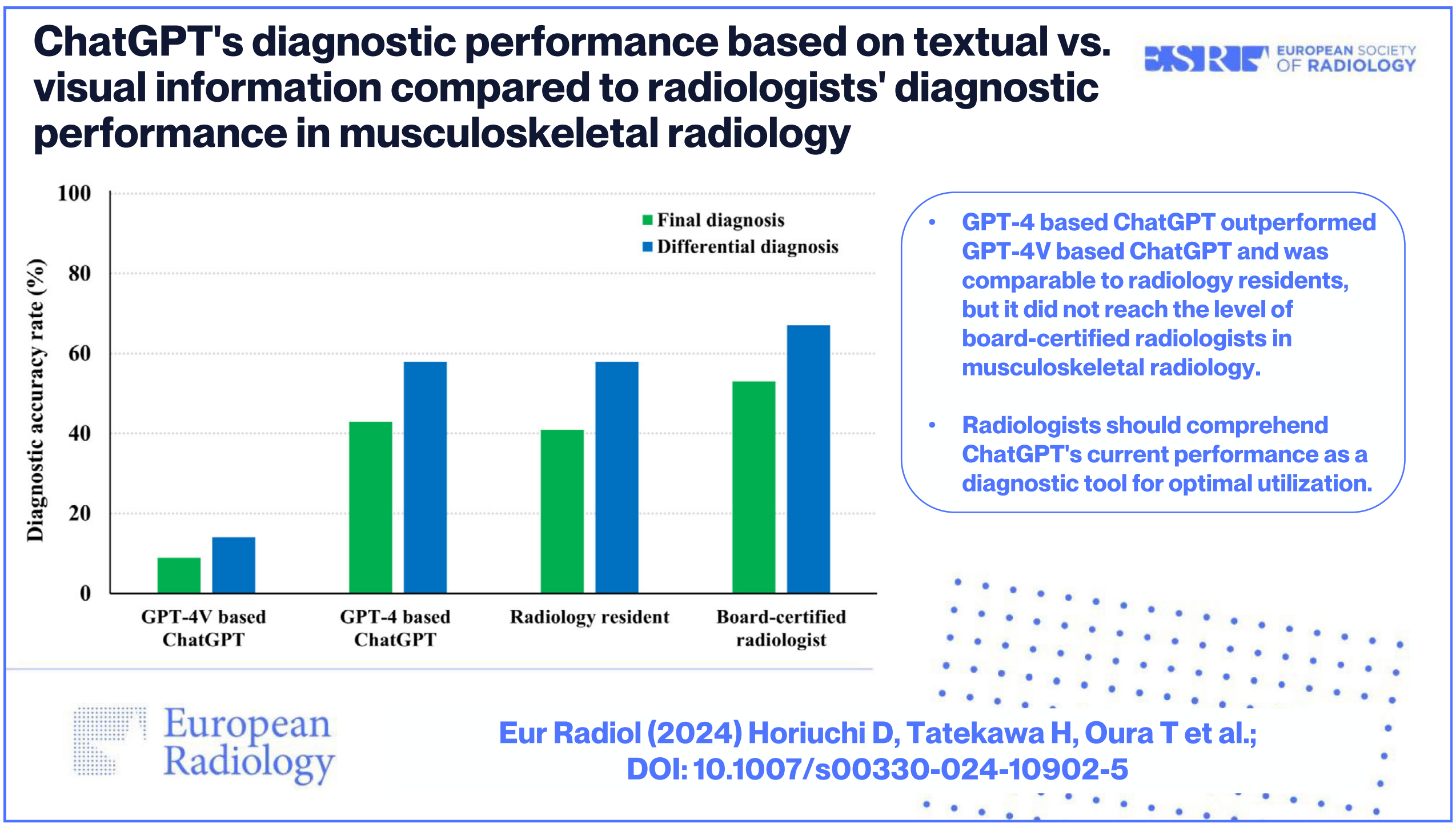

Introduction

Chat Generative Pre-trained Transformer (ChatGPT) is a novel language model based on GPT-4 architecture, which demonstrates an impressive capability for understanding and generating natural responses on various topics [1–3]. Experts in various industries have been exploring the potential applications of ChatGPT and considering how its integration could improve efficiency and decision-making processes [4]. Furthermore, the recent GPT-4 with vision (GPT-4V) enables the analysis of image inputs and offers the possibility of expanding the impact of large language models [5]. Given the potential impact of ChatGPT in the medical field, healthcare professionals need to understand its performance, strengths, and limitations for optimal utilization.

Artificial intelligence has demonstrated notable benefits in the field of radiology [6, 7], and it also holds promise for improving diagnostic accuracy and patient outcomes in musculoskeletal radiology [8, 9]. ChatGPT has the potential to be a valuable tool in improving diagnostic accuracy and patient outcomes, and there have been some initial applications of ChatGPT in radiology [10–17]. GPT-3.5-based ChatGPT nearly passed a text-based radiology examination without any specific radiology training, and then GPT-4-based ChatGPT passed the examination [18, 19]. In musculoskeletal radiology, there has been only one study of ChatGPT, which focused on generating research articles [20].

Previous studies have evaluated the diagnostic performance of GPT-4-based ChatGPT from the patient's medical history and imaging findings in the field of radiology [14, 17]. However, it remains unclear how ChatGPT's diagnostic accuracy compares when using the images themselves (GPT-4V-based ChatGPT) or the written descriptions of imaging findings (GPT-4-based ChatGPT). Additionally, the comparison of diagnostic performance among GPT-4-based ChatGPT, GPT-4V-based ChatGPT, and radiologists has not been investigated. Current data are insufficient to determine whether the integration of ChatGPT into musculoskeletal radiology practice has the potential to improve diagnostic accuracy and reduce diagnostic errors.

The journal *Skeletal Radiology* presents diagnostic cases as "Test Yourself" to allow readers to assess their diagnostic skills. These diagnostic cases offer a means to evaluate the diagnostic performance of ChatGPT in musculoskeletal radiology and obtain insights into its potential as a diagnostic tool.

This study aimed to compare the diagnostic accuracy among GPT-4-based ChatGPT, GPT-4V-based ChatGPT, and radiologists in musculoskeletal radiology using the "Test Yourself" cases published in *Skeletal Radiology*.

Materials and methods

Study design

This study was approved by the institutional review board of our institution, and informed consent was not required since this study utilized only published cases. We input the patient's medical history and descriptions of imaging findings associated with each case into GPT-4-based ChatGPT, and input the patient's medical history and images themselves associated with each case into GPT-4V-based ChatGPT. Each ChatGPT generated the differential and final diagnoses, and we estimated the diagnostic accuracy rate of the outputs. Additionally, radiologists independently reviewed all the cases based on the patient's medical history and images, and their diagnostic accuracy rates were evaluated. We then compared the diagnostic accuracy rates for the final diagnosis and differential diagnoses among GPT-4-based ChatGPT, GPT-4V-based ChatGPT, and radiologists. This study was designed according to the Standards for Reporting Diagnostic Accuracy Studies statement [21].

Data collection

The journal *Skeletal Radiology* publishes diagnostic cases in the "Test Yourself" section. We collected 128 consecutive "Test Yourself" cases from January 2014 (volume 43, issue 1) to September 2023 (volume 52, issue 9). We excluded 22 cases due to a lack of imaging findings text in the presented cases, and ultimately a total of 106 cases were included in this study. Each patient's medical history and images (excluding pathological images) were collected from the "Question" section, and the descriptions of imaging findings were collected from the "Answer" section of each published case. The "Answer" section contained descriptions of biopsy/surgical findings, histopathological findings, final/differential diagnoses, and discussion of diagnosis; thus, we excluded these descriptions from imaging findings. The data collection flowchart is presented in Fig. 1.

Input and output procedure for ChatGPT

First, the following premise was input into ChatGPT based on GPT-4 architecture (September 25 Version; OpenAI; https://chat.openai.com/) to prime it for the task: "As a physician, I plan to utilize you for research purposes. Assuming you are a hypothetical physician, please walk me through the process from differential diagnosis to the most likely disease step by step, based on the patient's

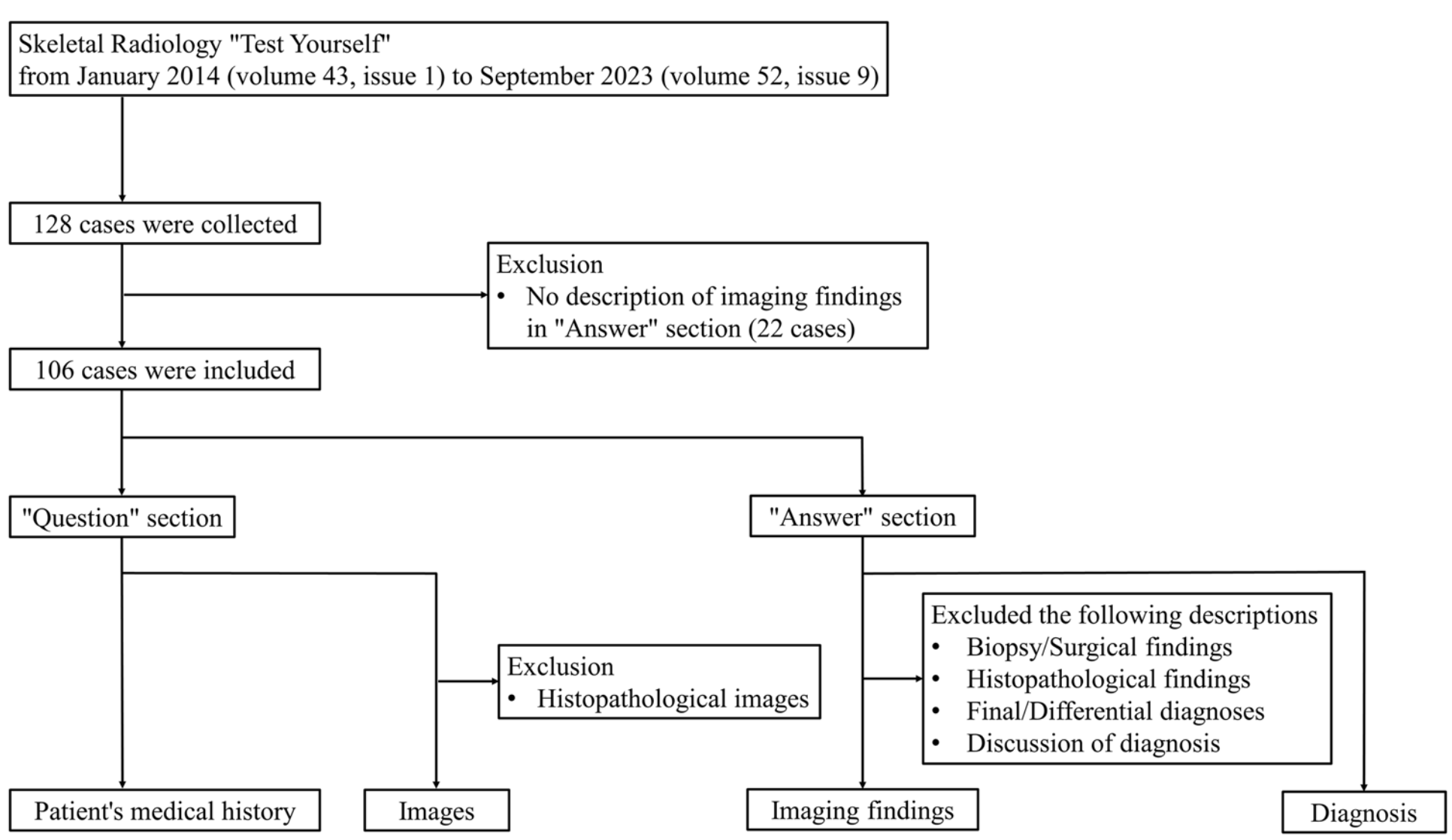

Fig. 1 Data collection flowchart

a

History
A 64-year-old woman presented with two palpable subcutaneous masses in her right distal arm. One mass was painful to touch and the other was painless. Two masses were identified on the ultrasound. Subsequent MRI was performed before and after intravenous contrast administration. Ultrasound-guided core biopsy was performed on the painful mass under local anesthesia to evaluate histology. The painless mass was not biopsied.

Imaging findings
The ultrasound of the right arm revealed the painful and painless solid masses within the subcutaneous tissue abutting the skin. Both masses showed heterogenous hyperechogenicity relative to the subcutaneous fat. The painful mass showed vascular flow on the color Doppler, whereas the painless mass did not show vascular flow, probably due to thinner capillaries and slow flow below the Doppler threshold. On MR images, both masses had an elliptical shape. On T1-weighted images, both masses consisted of fatty components with curvilinear and confluent areas of decreased signal and abutting the skin. On T2-weighted fat-suppressed images and post-contrast T1-weighted fat-suppressed images, the curvilinear areas showed high T2 signal and contrast enhancement, consistent with vessels.

b

Given the provided history and imaging findings, let's proceed with formulating differential diagnoses:

Patient Information Summary:

- **Age/Gender**: 64-year-old female
- **Clinical**: Two palpable subcutaneous masses in the right distal arm; one painful, one painless.
- **Ultrasound**: Both masses are well-circumscribed, hyperechoic to subcutaneous fat, and abut the skin. The painful mass shows internal and peripheral vascularity, while the painless mass lacks internal vascularity (suggesting thinner capillaries below the Doppler threshold).
- **MRI**: Both masses contain fatty subcutaneous lesions with a thin peripheral capsule and internal curvilinear foci. There is mild contrast enhancement within these curvilinear foci, consistent with capillary structures.

Differential Diagnoses:

1. **Lipoma with Intratumoral Vessels**:
   - **Rationale**: Lipomas are benign tumors composed of mature fat cells and are the most common soft-tissue tumors in adults. The presence of fatty subcutaneous lesions on MRI supports the diagnosis of lipomas. The intratumoral vessels within the painful mass might cause the pain due to increased blood flow or stretching of the tissue.
2. **Angiolipoma**:
   - **Rationale**: Angiolipomas are a subtype of lipoma characterized by a combination of mature adipose tissue and proliferative vascular channels. The painful nature of one mass and the presence of internal and peripheral vascularity on ultrasound, as well as the mild contrast enhancement within the curvilinear foci on MRI (suggesting capillary structures), support the diagnosis of angiolipoma for at least the painful mass.
3. **Lipoma Arborescens**:
   - **Rationale**: Lipoma arborescens is a rare, benign lesion characterized by villous proliferation of mature adipose tissue in synovial lining, which is unlikely in this presentation but may still be considered given the fatty nature of the lesion and its vascularity. However, this is generally seen in joint spaces and not in the described location.

Most Likely Diagnosis:
Given the findings and the patient's clinical presentation, an **Angiolipoma** seems to be the most likely diagnosis for the painful mass due to its combination of mature adipose tissue and proliferative vascular channels causing pain. The painless mass might be a simple lipoma or another angiolipoma that is yet to cause discomfort.

A biopsy of the painful mass should provide histological evidence to support or refute the proposed diagnoses. If the angiolipoma diagnosis is confirmed, the painless mass can also be assumed to be an angiolipoma based on its imaging characteristics, even though it was not biopsied.

Fig. 2 Input (patient's medical history and imaging findings) and output examples of GPT-4-based ChatGPT. **a** Input texts to ChatGPT. **b** Output texts generated by ChatGPT. The differential diagnoses are outlined in blue and the final diagnosis is outlined in red. The final diagnosis generated by ChatGPT is correct in this case [33, 34]

a

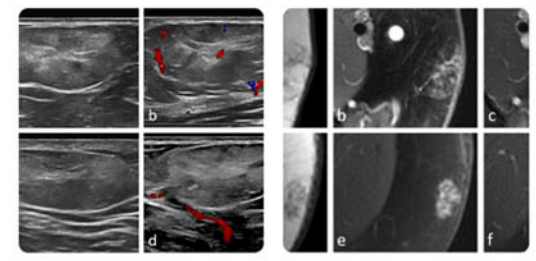

History
A 64-year-old woman presented with two palpable subcutaneous masses in her right distal arm. One mass was painful to touch and the other was painless. Two masses were identified on the ultrasound. Subsequent MRI was performed before and after intravenous contrast administration. Ultrasound-guided core biopsy was performed on the painful mass under local anesthesia to evaluate histology. The painless mass was not biopsied.

b

Given the provided ultrasound and MRI images and the patient's clinical presentation, we can begin the process of differential diagnosis:

Clinical Presentation:

- 64-year-old woman
- Two palpable subcutaneous masses in right distal arm
- One mass painful to touch, the other painless

Imaging Observations:

1. **Ultrasound Images:**
   - Image a displays a hypoechoic, possibly solid, lesion.
   - Image b shows color Doppler with flow, indicating vascularity of the lesion.
   - Images c and d provide additional views, with d showing the vascular nature of another lesion.
2. **MRI Images:**
   - The lesions appear hypointense in some of the provided images (a & b).
   - In some images, the lesion exhibits a hyperintense signal (c & d).
   - After the administration of intravenous contrast, there seems to be enhancement of the lesions (e & f), suggesting vascularity and possible permeability of the mass.

Differential Diagnoses:

1. **Angiolipoma:** Given the patient's age, the imaging characteristics, and clinical presentation (painful mass), angiolipoma is a prime suspect. These are benign lesions but can be painful due to their vascular component. The vascularity observed in the images supports this diagnosis.
2. **Neurofibroma or Schwannoma:** Given the patient's age and the characteristics of the masses on MRI (especially post-contrast enhancement), benign nerve sheath tumors like neurofibroma or schwannoma are possible. They can sometimes be painful and may exhibit post-contrast enhancement.
3. **Soft Tissue Sarcoma:** The patient's age, combined with the vascularity and heterogeneity of the lesion on imaging, makes soft tissue sarcoma a potential diagnosis. While less common than benign lesions, the possibility of malignancy should always be considered.

Most Likely Diagnosis: Based on the provided images and the clinical history, the most likely diagnosis is **Angiolipoma**. This diagnosis fits with the patient's age, the vascularity of the lesion on imaging, and the clinical symptom of pain. However, it is crucial to consider further investigations, such as biopsy, to confirm the diagnosis and rule out other potential pathologies, especially any malignant conditions. Collaboration with a radiologist and pathologist is crucial for comprehensive diagnostic evaluation.

Fig. 3 Input (patient's medical history and images) and output examples of GPT-4V-based ChatGPT. **a** Input to ChatGPT. **b** Output texts generated by ChatGPT. The differential diagnoses are outlined in blue and the final diagnosis is outlined in red. The final diagnosis generated by ChatGPT is correct in this case [33, 34]

information I am about to present. Please list three possible differential diagnoses in order of likelihood" [14, 22]. Then, for GPT-4-based ChatGPT, the patient's medical history and descriptions of imaging findings were input while, for GPT-4V-based ChatGPT, the patient's medical history and images themselves were input.

a

History
A 17-year-old female patient presented with a 4-week history of a painless, hard lump on the volar aspect of the right wrist. Range of movement, distal neurovascular examination and the overlying skin were normal. There was no history of trauma.

Imaging findings
Radiographs showed an extra-osseous, well-defined ossified mass arising from the volar, distal radial metadiaphysis with a lobular 'cauliflower-like' morphology. There was adjacent cortical thickening but no overt cortical destruction or aggressive periosteal reaction. CT showed stippled mineralisation extending from the volar aspect of the cortex with medullary continuity. The lesion had a broad base and was more ossified centrally than peripherally, with no appreciable soft tissue mass or cortical destruction. MRI demonstrated a dome-shaped mass measuring 14 × 12 × 10 mm arising from the volar radial cortex. This was of heterogeneous low T1W SI and heterogeneous intermediate-to-low T2W SI centrally with thin peripheral hyperintensity suggestive of a poorly defined cartilage cap. Involvement of the cortex was optimally demonstrated on the post-contrast fat-suppressed T1W TSE image sequences with minor underlying marrow abnormality suggestive of early medullary involvement.

b

Based on the information provided for this 17-year-old female patient with a painless, hard lump on the volar aspect of the right wrist, here's how I would approach this case from differential diagnosis to the most likely disease, assuming the role of a hypothetical physician:

Step 1: Gathering Information

- **Patient Age and Gender**: 17-year-old female
- **Chief Complaint**: Painless, hard lump on the volar aspect of the right wrist for 4 weeks
- **Significant Findings**:
  - No history of trauma
  - Normal range of movement and neurovascular examination
  - Radiographs reveal an extra-osseous, well-defined ossified mass with a 'cauliflower-like' morphology
  - CT shows stippled mineralization with medullary continuity, more ossified centrally
  - MRI demonstrates a dome-shaped mass with a poorly defined cartilage cap and early medullary involvement

Step 2: Differential Diagnosis

Given the patient's age, clinical presentation, and imaging findings, three potential differential diagnoses are:

1. **Osteochondroma**: This is the most likely diagnosis. Osteochondromas are common benign bone tumors that often present in the second decade of life. The imaging characteristics, such as a well-defined ossified mass with a cartilage cap and continuity with the underlying bone marrow, are classic features of osteochondromas. The 'cauliflower-like' appearance and the location on the wrist support this diagnosis.
2. **Parosteal Osteosarcoma**: While this is a rare entity, especially in this age group, it could present as a well-differentiated, ossified mass arising from the cortex. The absence of aggressive periosteal reaction and cortical destruction on imaging makes this less likely than an osteochondroma. However, the presence of stippled mineralization and the involvement of the cortex may raise suspicion.
3. **Chondroma**: Specifically, periosteal (juxtacortical) chondroma could also present similarly but is less likely given the ossification pattern and medullary continuity seen in the imaging. Chondromas are benign cartilage-forming tumors that usually present as a painless mass, but the imaging findings of this case favor an osteochondroma over a chondroma.

Step 3: Most Likely Diagnosis

The most likely diagnosis for this patient is an **Osteochondroma**. The imaging findings of a well-defined ossified mass with a 'cauliflower-like' morphology, stippled mineralization, a broad base with more ossification centrally than peripherally, and a poorly defined cartilage cap are typical features of an osteochondroma. The lesion's growth from the cortex with continuity of the marrow space further supports this diagnosis.

Fig. 4 A challenging case example for GPT-4-based ChatGPT. **a** Input texts (patient's medical history and imaging findings) to ChatGPT. **b** Output texts generated by ChatGPT. The differential diagnoses are outlined in blue and the final diagnosis is outlined in red. While the differential diagnoses generated by ChatGPT include the correct diagnosis, the final diagnosis is incorrect in this case (true diagnosis: parosteal osteosarcoma) [35, 36]

The subsequent output from ChatGPT was collected (as shown in Figs. 2–5). We started a new ChatGPT session for each case to prevent any potential influence of previous answers on ChatGPT's output. These procedures were performed once for each case between September 28 and October 6, 2023.

a

History
A 17-year-old female patient presented with a 4-week history of a painless, hard lump on the volar aspect of the right wrist. Range of movement, distal neurovascular examination and the overlying skin were normal. There was no history of trauma.

b

Based on the provided information and imaging studies, here is how I would approach this case:

1. Review of Imaging:

- **X-Ray (Figure 1):** This image appears to show the wrist in lateral view. We should look for any bone abnormalities, such as changes in bone density, fractures, or abnormal growths.
- **CT Scan (Figure 2):** This cross-sectional imaging provides detailed information about the bone structure and can identify any subtle lesions or changes not evident on the X-ray.
- **MRI Images (Figure 3):** MRI provides detailed images of soft tissue and bone marrow. It can help differentiate between benign and malignant lesions, and characterize soft tissue abnormalities.

2. Clinical Correlation:

- The patient is a 17-year-old female with a painless, hard lump on the volar aspect of the wrist without a history of trauma.
- Normal range of movement, neurovascular examination, and overlying skin indicate that the lesion might be confined without involving surrounding structures aggressively.

3. Differential Diagnoses:

- **Ganglion cyst:** The most common mass in the wrist, typically non-painful, and can be firm. However, a ganglion cyst is usually not hard, and they are better evaluated with MRI or ultrasound.
- **Osteoid osteoma:** A benign bone tumor that typically presents with pain that is worse at night and relieved by NSAIDs. However, the absence of pain in this patient makes this less likely.
- **Enchondroma:** A common benign bone tumor that arises from cartilage, which could present as a hard lump and usually is painless. MRI and CT can help identify the classic appearance.

The imaging provided seems to indicate a solitary lesion in the wrist with a clear delineation between the lesion and surrounding bone tissue. The lack of aggressive features and a painless presentation leans more towards a benign process.

Given the details, a presumptive diagnosis would lean towards a benign lesion, such as a ganglion cyst or an enchondroma. However, the definitive diagnosis would depend on the integration of imaging findings with the clinical picture and possibly histological examination if a biopsy is performed.

Fig. 5 A challenging case example for GPT-4V-based ChatGPT. **a** Input (patient's medical history and images) to ChatGPT. **b** Output texts generated by ChatGPT. The differential diagnoses are outlined in blue; however, ChatGPT's diagnosis is incorrect in this case (true diagnosis: parosteal osteosarcoma) [35, 36]

Output evaluation and category classification

The output generated by GPT-4-based ChatGPT and GPT-4V-based ChatGPT included three differential diagnoses and one final diagnosis. Two board-certified radiologists (13 years of experience [H.T.]; 7 years of experience [D.H.]) evaluated both the differential diagnoses and the final diagnosis generated by ChatGPT to determine whether they were consistent with the actual ground truth in consensus (we defined the differential diagnosis as correct if the three provided differential diagnoses included the actual ground truth). Each case was categorized into two groups: the tumor group and the nontumor group, according to the 2020 World Health Organization classification of soft tissue and bone tumors [23]. The cases in the tumor group were further divided into bone tumor and soft tissue tumor cases. Additionally, the cases in the nontumor group were categorized by disease etiology as follows: muscle/soft tissue/nerve disorder, arthritis/arthropathy, infection, congenital/developmental abnormality and dysplasia, trauma, metabolic disease, anatomical variant, and others [24].

Radiologists' interpretation

Two radiologists with different levels of experience (Reader 1 [T.O.]; a radiology resident with 4 years of experience) and (Reader 2 [D.H.]; a board-certified radiologist with 7 years of experience) independently reviewed all 106 cases. Both radiologists conducted their diagnoses based on the patient's medical history and images (from the "Question" section). They provided three differential diagnoses and chose one as the final diagnosis for each case, and the diagnostic accuracy rates were evaluated. Both radiologists were blinded to the actual ground truth, as well as the differential and final diagnoses generated by ChatGPT.

Radiologists' interpretation with ChatGPT's assistance

Following the initial interpretation, both radiologists independently reviewed all cases again, referencing the differential and final diagnoses generated by GPT-4-based ChatGPT and GPT-4V-based ChatGPT, respectively. They provided three differential diagnoses and chose one as the final diagnosis for each case, and the diagnostic accuracy rates with ChatGPT's assistance were evaluated. Both radiologists were blinded to the actual ground truth.

Statistical analysis

Statistical analyses were performed using R software (version 4.0.2, 2020; R Foundation for Statistical Computing; http://www.r-project.org/). Chi-square tests were conducted to compare the final and differential diagnostic accuracy rates between GPT-4-based ChatGPT and GPT-4V-based ChatGPT. Chi-square tests were also conducted to compare the final and differential diagnostic accuracy rates between GPT-4-based ChatGPT and each radiologist, as well as between GPT-4V-based ChatGPT and each radiologist. Furthermore, ChatGPT's final and differential diagnostic accuracy rates for 1) the tumor and nontumor groups, and 2) the bone tumor and soft tissue tumor cases were compared with pairwise Fisher's exact tests. Adjustment for multiplicity was not performed because this was an exploratory study. $p < 0.05$ was considered statistically significant.

Results

ChatGPT's diagnostic accuracy: GPT-4-based ChatGPT vs GPT-4V-based ChatGPT

In all 106 cases, GPT-4-based ChatGPT (based on the patient's medical history and imaging findings) and GPT-4V-based ChatGPT (based on the patient's medical history and images) successfully generated three differential diagnoses and provided one final diagnosis. GPT-4-based ChatGPT's diagnostic accuracy rates for the final and differential diagnoses were 43% (46/106) and 58% (62/106), respectively. In contrast, GPT-4V-based ChatGPT's diagnostic accuracy rates for the final and differential diagnoses were 8% (9/106) and 14% (15/106), respectively. Both the final and differential diagnostic accuracy rates were significantly higher for GPT-4-based ChatGPT compared to GPT-4V-based ChatGPT ($p < 0.001$ and < 0.001, respectively).

Comparison of the diagnostic accuracy between ChatGPT and radiologists

Regarding the radiologists' diagnostic accuracy, Reader 1 (a radiology resident) achieved a final diagnostic accuracy of 41% (43/106) and a differential diagnostic accuracy of 58% (61/106). Reader 2 (a board-certified radiologist) achieved a final diagnostic accuracy of 53% (56/106) and a differential diagnostic accuracy of 67% (71/106).

GPT-4-based ChatGPT's diagnostic accuracy rates for the final and differential diagnoses were comparable and not statistically significantly different from those of Reader 1 ($p = 0.78$ and 0.99, respectively), but lower than those of Reader 2, though not significantly ($p = 0.22$ and 0.26, respectively) (Table 1) (Fig. 6). In contrast, GPT-4V-based ChatGPT's diagnostic accuracy rates for the final and differential diagnoses were significantly lower than those of both radiologists (all $p < 0.001$).

Radiologists' diagnostic accuracy with ChatGPT's assistance

Reader 1's diagnostic accuracy increased from 41% (43/106) to 46% (49/106) for final diagnoses and from 58% (61/106) to 64% (68/106) for differential diagnoses with the assistance of GPT-4-based ChatGPT. Similarly, Reader 2's diagnostic accuracy increased from 53% (56/106) to 58% (62/106) for final diagnoses and from 67% (71/106) to 73% (77/106) for differential diagnoses with the assistance of GPT-4-based ChatGPT. In contrast, with the assistance of GPT-4V-based ChatGPT, there was no

Table 1 Comparison of the diagnostic accuracy between ChatGPT and radiologists

	Correct answer (accuracy rate [%])			
	Final diagnosis	***p* value***	**Differential diagnosis**	***p* value***
GPT-4-based ChatGPT	46/106 (43%)		62/106 (58%)	
Reader 1 (Radiology resident)	43/106 (41%)	0.78	61/106 (58%)	0.99
Reader 2 (Board-certified radiologist)	56/106 (53%)	0.22	71/106 (67%)	0.26
GPT-4V-based ChatGPT	9/106 (8%)		15/106 (14%)	
Reader 1 (Radiology resident)	43/106 (41%)	< 0.001**	61/106 (58%)	< 0.001**
Reader 2 (Board-certified radiologist)	56/106 (53%)	< 0.001**	71/106 (67%)	< 0.001**

ChatGPT Chat Generative Pre-trained Transformer, *GPT-4* Generative Pre-trained Transformer-4, *GPT-4V* Generative Pre-trained Transformer-4 with vision
*Chi-square tests are performed to compare the accuracy rates between GPT-4-based ChatGPT and each radiologist, as well as between GPT-4V-based ChatGPT and each radiologist
**$p < 0.05$

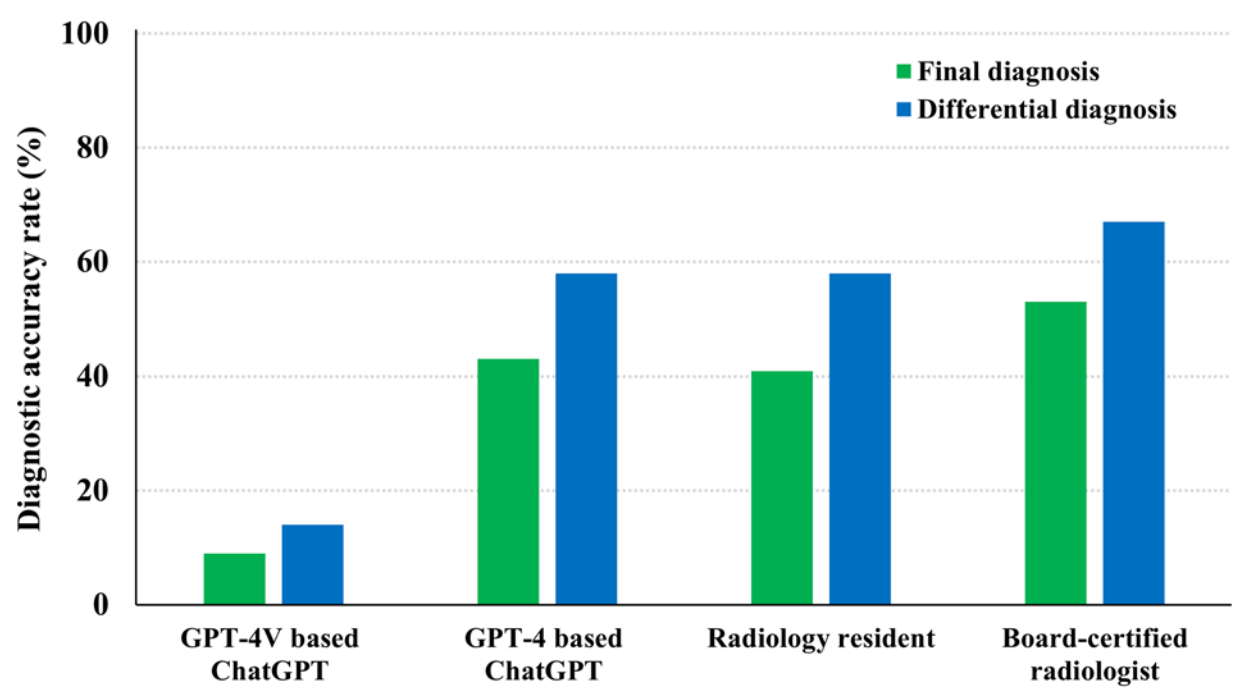

Fig. 6 Diagnostic accuracy of GPT-4-based ChatGPT, GPT-4V-based ChatGPT, and radiologists

improvement in diagnostic accuracy for either Reader 1 or Reader 2.

Categorical analysis of ChatGPT's diagnostic accuracy

Detailed diagnostic accuracy rates for ChatGPT are shown in Table 2. Given the limited number of correct diagnoses by GPT-4V-based ChatGPT, a categorical analysis was considered inappropriate due to the limited statistical power. Thus, we conducted a categorical analysis only for GPT-4-based ChatGPT's diagnostic accuracy.

When comparing the tumor and nontumor groups, the final and differential diagnostic accuracy rates were 31% (14/45) and 49% (22/45) for the tumor group, and 52% (32/61) and 66% (40/61) for the nontumor group, respectively. The tumor group showed significantly lower final diagnostic accuracy rates compared to the nontumor group ($p = 0.03$), while there was no significant difference between the differential diagnostic accuracy rates of the two groups ($p = 0.11$). Within the tumor group, the final and differential diagnostic accuracy rates were 33% (8/24) and 58% (14/24) in bone tumor cases, and 27% (6/22) and 41% (9/22) in soft tissue tumor cases, respectively (one presented both a bone tumor and a soft tissue tumor). When comparing the diagnostic accuracy rates between bone tumor and soft tissue tumor cases, no significant difference was observed in either the final or differential diagnosis ($p = 0.75$ and 0.38, respectively).

The diagnostic accuracy rates for the nontumor etiologies are presented in Table 3. GPT-4-based ChatGPT demonstrated relatively higher final diagnostic accuracy for congenital/developmental abnormality and dysplasia, trauma, and anatomical variant categories. In contrast, its final diagnostic accuracy was relatively lower for arthritis/arthropathy, infection, and metabolic disease categories.

Discussion

This study demonstrated the diagnostic accuracy of GPT-4-based ChatGPT and GPT-4V-based ChatGPT in musculoskeletal radiology. The diagnostic accuracy of GPT-4-based ChatGPT (based on the patient's medical history and imaging findings) was significantly higher than that of GPT-4V-based ChatGPT (based on the patient's medical history and images). Regarding the comparison between ChatGPT and radiologists, GPT-4-based ChatGPT's diagnostic accuracy was comparable to that of a radiology resident but lower than that of a board-certified radiologist. While GPT-4V-based ChatGPT's diagnostic accuracy was significantly lower than that of both radiologists. The diagnostic accuracy of radiologists improved with GPT-4-based ChatGPT's assistance, but not with GPT-4V-based ChatGPT's assistance. In the analysis of GPT-4-based ChatGPT's diagnostic accuracy per category, GPT-4-based ChatGPT's final diagnostic accuracy rate was significantly lower for the tumor group compared to the nontumor group. Within the tumor group, the accuracy rates for the final and differential diagnoses were relatively higher for bone tumor cases compared to those of soft tissue tumor cases, although the differences were not significant.

Table 2 ChatGPT's diagnostic accuracy categorized by tumor and nontumor groups

	Correct answer (accuracy rate [%])			
	GPT-4-based ChatGPT		GPT-4V-based ChatGPT	
	Final diagnosis	Differential diagnosis	Final diagnosis	Differential diagnosis
Total (*n* = 106)	46/106 (43%)	62/106 (58%)	9/106 (8%)	15/106 (14%)
Tumor group (*n* = 45)	14/45 (31%)	22/45 (49%)	4/45 (9%)	5/45 (11%)
Nontumor group (*n* = 61)	32/61 (52%)	40/61 (66%)	5/61 (8%)	10/61 (16%)
Tumor group (*n* = 45)[a]	14/45 (31%)	22/45 (49%)	4/45 (9%)	5/45 (11%)
Bone tumor (*n* = 24)	8/24 (33%)	14/24 (58%)	2/24 (8%)	3/24 (13%)
Soft tissue tumor (*n* = 22)	6/22 (27%)	9/22 (41%)	2/22 (9%)	2/22 (10%)

ChatGPT Chat Generative Pre-trained Transformer, *GPT-4* Generative Pre-trained Transformer-4, *GPT-4V* Generative Pre-trained Transformer-4 with vision
[a]One case presents both a bone tumor and a soft tissue tumor

Table 3 ChatGPT's diagnostic accuracy in nontumor etiologies

	Correct answer (accuracy rate [%])			
	GPT-4-based ChatGPT		GPT-4V-based ChatGPT	
	Final diagnosis	Differential diagnosis	Final diagnosis	Differential diagnosis
Muscle/soft tissue/nerve disorder (*n* = 12)	7/12 (58%)	11/12 (92%)	2/12 (17%)	3/12 (25%)
Arthritis/arthropathy (*n* = 10)	4/10 (40%)	4/10 (40%)	1/10 (10%)	1/10 (10%)
Infection (*n* = 8)	3/8 (38%)	5/8 (63%)	0/8 (0%)	1/8 (13%)
Congenital/developmental abnormality and dysplasia (*n* = 6)	4/6 (67%)	4/6 (67%)	0/6 (0%)	0/6 (0%)
Trauma (*n* = 6)	5/6 (83%)	5/6 (83%)	1/6 (17%)	2/6 (33%)
Metabolic disease (*n* = 5)	2/5 (40%)	3/5 (60%)	0/5 (0%)	0/5 (0%)
Anatomical variant (*n* = 4)	3/4 (75%)	3/4 (75%)	0/4 (0%)	0/4 (0%)
Others (*n* = 10)	4/10 (40%)	5/10 (50%)	1/10 (10%)	3/10 (30%)

ChatGPT Chat Generative Pre-trained Transformer, *GPT-4* Generative Pre-trained Transformer-4, *GPT-4V* Generative Pre-trained Transformer-4 with vision

To the best of our knowledge, this study is the first in the field of musculoskeletal radiology to investigate the diagnostic capability of GPT-4 and GPT-4V-based ChatGPTs and to compare these to radiologists' performance. Although a previous study has reported that GPT-3-based ChatGPT can generate coherent research articles in musculoskeletal radiology [20], no study has evaluated the diagnostic performance of GPT-4 and GPT-4V-based ChatGPTs in this field. This study provides valuable insights into the strengths and limitations of using ChatGPT as a diagnostic tool in musculoskeletal radiology.

While ChatGPT holds promise as a useful tool in musculoskeletal radiology, radiologists should recognize its capabilities and exercise caution when incorporating ChatGPT into clinical practice. This study demonstrated that the diagnostic accuracy of GPT-4-based ChatGPT was significantly higher than that of GPT-4V-based ChatGPT. These results indicated that the GPT-4V-based ChatGPT's capability to process images and extract imaging findings is insufficient. A recent study has reported that GPT-4V-based ChatGPT exhibited limited interpretive accuracy in analyzing radiological images [25]. One factor contributing to the underperformance of GPT-4V-based ChatGPT was perhaps its insufficient training in medical images. In OpenAI's statements, they considered the current GPT-4V to be unsuitable for performing the interpretation of medical images and replacing professional medical diagnoses due to inconsistencies [5]. For further improvements of GPT-4V-based ChatGPT's diagnostic accuracy, exploring techniques such as retrieval-augmented generation, fine-tuning with reinforcement learning from human feedback, and training vision models on a wide range of medical images should be considered [26]. Since textual information is the only feasible support option to date, providing the appropriate description of imaging findings is crucial when utilizing ChatGPT as a diagnostic tool in clinical practice. Regarding the comparison between ChatGPT and radiologists, GPT-4V-based ChatGPT's diagnostic performance was significantly lower than that of radiologists, and GPT-4-based ChatGPT's diagnostic performance was comparable to that of radiology residents but did not reach the performance level of board-certified radiologists. ChatGPT may assist radiologists in the diagnostic process; however, ChatGPT alone cannot fully replace the expertise of radiologists and should only be used as an adjunct tool.

Although GPT-4-based ChatGPT alone cannot replace the expertise of radiologists, it is capable of enhancing diagnostic accuracy and assisting radiologists in narrowing down differential diagnoses as part of the diagnostic workflow in musculoskeletal radiology. Furthermore, ChatGPT has been shown to provide valuable assistance to radiologists in various tasks, including supporting decision-making, determining imaging protocols, generating radiology reports, offering patient education, and writing medical publications [26, 27]. The implementation of ChatGPT into radiological practices has the potential to optimize the diagnostic process, resulting in time savings and a decreased workload for radiologists, thereby increasing overall efficiency.

This study also revealed that the diagnostic accuracy of GPT-4-based ChatGPT may vary depending on the etiology of the disease; it was significantly lower in the tumor group compared to the nontumor group. This lower diagnostic accuracy in neoplastic diseases could be attributed to the challenging nature of interpreting complex cases, due to the wide variety of histopathological types and imaging findings [23, 28]. Rare neoplastic diseases may be more challenging for ChatGPT due to the limited literature and a lack of established typical imaging findings. Although no significant difference in diagnostic accuracy rates was observed between bone tumor and soft tissue tumor cases, bone tumor cases showed relatively higher accuracy rates compared to soft tissue tumor cases. While soft tissue tumors of both benign and malignant nature often share overlapping imaging features [29], bone tumors have grading systems that allow for the assessment of malignancy risk based on their growth patterns [30, 31]. This distinction may be one of the contributing factors to the relatively higher differential diagnostic accuracy for bone tumors compared to soft tissue tumors. On the other hand, the significantly higher accuracy rates for the final diagnosis of the nontumor group indicated that GPT-4-based ChatGPT may be particularly useful in diagnosing non-neoplastic diseases in musculoskeletal radiology. Among non-neoplastic diseases, cases of congenital/developmental abnormality and dysplasia, traumatic disease, and anatomical variants showed relatively higher final diagnostic accuracy. These relatively higher accuracies may be attributed to characteristic keywords in patient's medical history and imaging findings for these conditions.

This study had several limitations. First, ChatGPT's performance in generating diagnoses was conducted in the controlled environment of the "Test Yourself" cases, which may not fully represent the broader range of musculoskeletal radiology cases. This selection bias could affect the generalizability of the results and may not capture the full spectrum of diagnostic challenges encountered in real-world clinical practice. Second, the "Test Yourself" cases represent a potential for bias since these cases may have been included in the training data of ChatGPT. This bias may lead to an overestimation of ChatGPT's diagnostic accuracy. Third, this study utilized the descriptions of imaging findings provided by authors aware of the final diagnosis in the "Test Yourself" cases. This may have introduced a bias, which could lead to an overestimation of GPT-4-based ChatGPT's diagnostic accuracy. Further studies are necessary to mitigate this bias, including evaluating ChatGPT's diagnostic accuracy utilizing the descriptions of imaging findings provided by radiologists blinded to the final diagnosis. Fourth, radiologists' diagnoses with the assistance of ChatGPT may introduce a bias, potentially leading to an overestimation of ChatGPT's capabilities as a diagnostic support tool. Fifth, this study did not conduct a categorical analysis for GPT-4V-based ChatGPT's diagnostic accuracy due to the limited number of correct diagnoses, which limits the statistical power of the analyses. Sixth, this study did not perform a statistical analysis for ChatGPT's diagnostic accuracy in non-neoplastic etiologies due to the limited number of cases. Finally, this study did not investigate hallucinations, a critical limitation of large language models [25, 26, 32]. Radiologists need to be aware of hallucinations when utilizing ChatGPT as a diagnostic tool in clinical practice. Further studies are necessary to explore the characteristics and mitigation strategies of hallucinations for optimal utilization of ChatGPT.

In conclusion, this study evaluated the diagnostic accuracy of both GPT-4-based ChatGPT and GPT-4V-based ChatGPT in musculoskeletal radiology. When GPT-4-based ChatGPT utilized the descriptions of imaging findings provided by distinguished radiologists, its diagnostic performance was comparable to that of radiology residents but did not reach the performance level of board-certified radiologists. In contrast, GPT-4V-based ChatGPT, which independently evaluates imaging findings, showed poor diagnostic ability. Since textual information is the only feasible support option to date, providing the appropriate description of imaging findings is crucial when utilizing ChatGPT as a diagnostic tool in clinical practice. While ChatGPT may assist radiologists in narrowing down the differential diagnosis and improving the diagnostic workflow, radiologists need to be aware of its capabilities and limitations for optimal utilization.

Abbreviations

ChatGPT	Chat Generative Pre-trained Transformer
GPT-4	Generative Pre-trained Transformer-4
GPT-4V	Generative Pre-trained Transformer-4 with vision

Acknowledgements

Our manuscript was developed with the assistance of ChatGPT, a language model based on the GPT-4 architecture (September 25 Version; OpenAI; https://chat.openai.com/). However, all outputs generated by ChatGPT were reviewed and approved by the authors.

Funding

This study has received funding by Guerbet.

Compliance with ethical standards

Guarantor

The scientific guarantor of this publication is Daiju Ueda.

Conflict of Interest

The authors of this manuscript declare no relationships with any companies, whose products or services may be related to the subject matter of the article.

Statistics and biometry

No complex statistical methods were necessary for this paper.

Informed consent

Written informed consent was not required for this study because this study utilized published cases.

Ethical approval

Institutional Review Board approval was obtained.

Study subjects or cohorts overlap

No study subjects or cohorts have been previously reported.

Methodology

- Retrospective
- Diagnostic or prognostic study
- Performed at one institution

Received: 23 January 2024 Revised: 2 May 2024 Accepted: 24 June 2024
Published online: 12 July 2024

References

1. OpenAI (2023) GPT-4 technical report. arXiv [csCL]. https://doi.org/10.48550/arXiv.2303.08774
2. Brown TB, Mann B, Ryder N et al (2020) Language models are few-shot learners. arXiv [csCL]. https://doi.org/10.48550/arXiv.2005.14165
3. Bubeck S, Chandrasekaran V, Eldan R et al (2023) Sparks of artificial general intelligence: early experiments with GPT-4. arXiv [csCL]. https://doi.org/10.48550/arXiv.2303.12712
4. Eloundou T, Manning S, Mishkin P, Rock D (2023) GPTs are GPTs: an early look at the labor market impact potential of large language models. arXiv [econGN]. https://doi.org/10.48550/arXiv.2303.10130
5. OpenAI, GPT-4V(ision) system card (2023) Available via https://openai.com/research/gpt-4v-system-card. Accessed Oct 13 2023
6. Hosny A, Parmar C, Quackenbush J, Schwartz LH, Aerts H (2018) Artificial intelligence in radiology. Nat Rev Cancer 18:500–510
7. Ueda D, Shimazaki A, Miki Y (2019) Technical and clinical overview of deep learning in radiology. Jpn J Radiol 37:15–33
8. Chea P, Mandell JC (2020) Current applications and future directions of deep learning in musculoskeletal radiology. Skeletal Radiol 49:183–197
9. Shin Y, Kim S, Lee YH (2022) AI musculoskeletal clinical applications: how can AI increase my day-to-day efficiency? Skeletal Radiol 51:293–304
10. Haver HL, Ambinder EB, Bahl M, Oluyemi ET, Jeudy J, Yi PH (2023) Appropriateness of breast cancer prevention and screening recommendations provided by ChatGPT. Radiology 307:e230424
11. Adams LC, Truhn D, Busch F et al (2023) Leveraging GPT-4 for post hoc transformation of free-text radiology reports into structured reporting: a multilingual feasibility study. Radiology 307:e230725
12. Gertz RJ, Bunck AC, Lennartz S et al (2023) GPT-4 for automated determination of radiological study and protocol based on radiology request forms: a feasibility study. Radiology 307:e230877
13. Kottlors J, Bratke G, Rauen P et al (2023) Feasibility of differential diagnosis based on imaging patterns using a large language model. Radiology 308:e231167
14. Ueda D, Mitsuyama Y, Takita H et al (2023) ChatGPT's diagnostic performance from patient history and imaging findings on the diagnosis please quizzes. Radiology 308:e231040
15. Jeblick K, Schachtner B, Dexl J et al (2024) ChatGPT makes medicine easy to swallow: an exploratory case study on simplified radiology reports. Eur Radiol 34:2817–2825
16. Rosen S, Saban M (2024) Evaluating the reliability of ChatGPT as a tool for imaging test referral: a comparative study with a clinical decision support system. Eur Radiol 34:2826–2837
17. Horiuchi D, Tatekawa H, Shimono T et al (2024) Accuracy of ChatGPT generated diagnosis from patient's medical history and imaging findings in neuroradiology cases. Neuroradiology 66:73–79
18. Bhayana R, Krishna S, Bleakney RR (2023) Performance of ChatGPT on a radiology board-style examination: insights into current strengths and limitations. Radiology 307:e230582
19. Bhayana R, Bleakney RR, Krishna S (2023) GPT-4 in radiology: improvements in advanced reasoning. Radiology 307:e230987
20. Ariyaratne S, Iyengar KP, Nischal N, Chitti Babu N, Botchu R (2023) A comparison of ChatGPT-generated articles with human-written articles. Skeletal Radiol 52:1755–1758
21. Bossuyt PM, Reitsma JB, Bruns DE et al (2015) STARD 2015: an updated list of essential items for reporting diagnostic accuracy studies. Radiology 277:826–832
22. Li D, Gupta K, Chong J (2023) Evaluating diagnostic performance of ChatGPT in radiology: delving into methods. Radiology 308:e232082
23. WHO Classification of Tumours Editorial Board (2020) Soft tissue and bone tumors, 5th ed. International Agency for Research on Cancer, Lyon
24. Davis KW, Blankenbaker DG, Bernard S (2022) Diagnostic imaging: musculoskeletal non-traumatic disease, 3rd ed. Elsevier Health Sciences, Philadelphia
25. Deng J, Heybati K, Shammas-Toma M (2024) When vision meets reality: exploring the clinical applicability of GPT-4 with vision. Clin Imaging 108:110101
26. Bhayana R (2024) Chatbots and large language models in radiology: a practical primer for clinical and research applications. Radiology 310:e232756
27. Kim S, Lee CK, Kim SS (2024) Large language models: a guide for radiologists. Korean J Radiol 25:126–133
28. Murphey MD, Kransdorf MJ (2021) Staging and classification of primary musculoskeletal bone and soft-tissue tumors according to the 2020 WHO update, from the AJR special series on cancer staging. AJR Am J Roentgenol 217:1038–1052
29. Kransdorf MJ, Murphey MD (2016) Imaging of soft-tissue musculoskeletal masses: fundamental concepts. Radiographics 36:1931–1948
30. Caracciolo JT, Temple HT, Letson GD, Kransdorf MJ (2016) A modified lodwick-madewell grading system for the evaluation of lytic bone lesions. AJR Am J Roentgenol 207:150–156
31. Chang CY, Garner HW, Ahlawat S et al (2022) Society of Skeletal Radiology- white paper. Guidelines for the diagnostic management of

incidental solitary bone lesions on CT and MRI in adults: bone reporting and data system (Bone-RADS). Skeletal Radiol 51:1743–1764
32. Sasaki F, Tatekawa H, Mitsuyama Y et al (2024) Bridging language and stylistic barriers in IR standardized reporting: enhancing translation and structure using ChatGPT-4. J Vasc Interv Radiol 35:472–475.e1
33. Lombardi AF, Hameed M, Khan N, Hwang S (2023) Test yourself: soft tissue mass in elbow. Skeletal Radiol 52:1395–1397
34. Lombardi AF, Hameed M, Khan N, Hwang S (2023) Test yourself: soft tissue mass in elbow. Skeletal Radiol 52:1427–1429
35. Berkeley R, Lindsay D, Pollock R, Saifuddin A (2021) Painless wrist lump. Skeletal Radiol 50:1465–1466
36. Berkeley R, Lindsay D, Pollock R, Saifuddin A (2021) Painless wrist lump. Skeletal Radiol 50:1485–1487

Publisher's Note